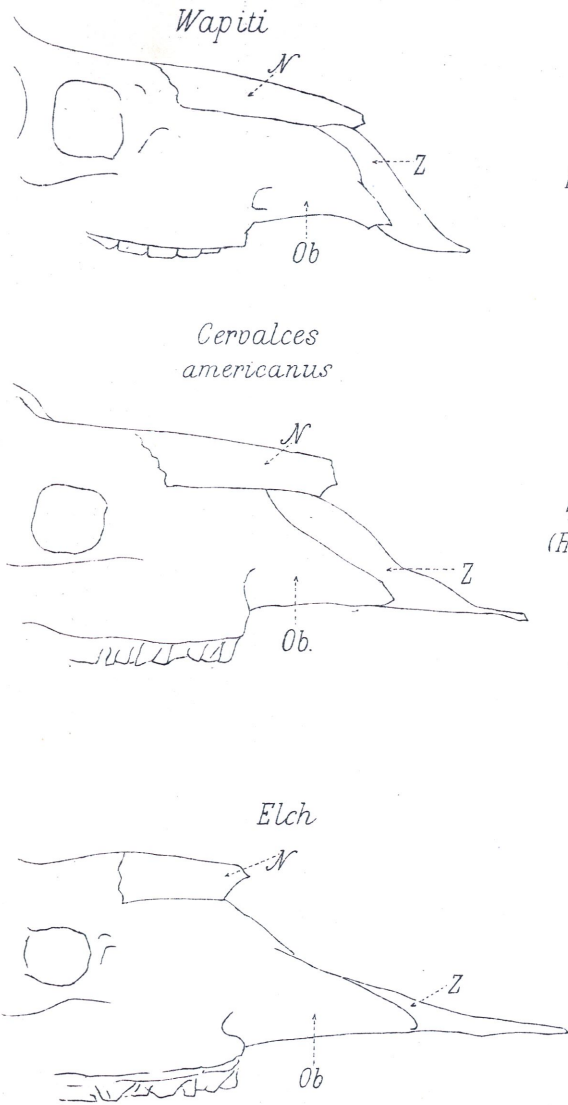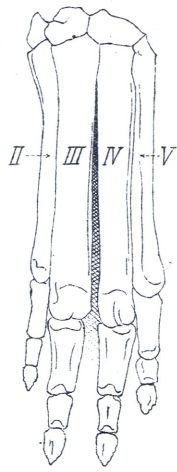
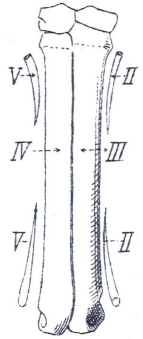


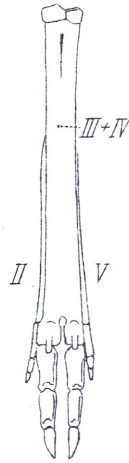
N. Nasenbein Z. - Zwischenkiefer
 Ob. - Oberkiefer




4 zehiger Fußs
 (Hyopotamus)



reducirter
 Artiodactylen-Fußs
 (Gelocus.)



Tele-
 metacarpaler
 Cervidenfuß
 (Reh)



Plesio-
 metacarpaler
 Edelhirsches Fuß
 (Edelhirsch)